

Definizione della Linfadenectomia Standard per la resezione delle lesioni Periapollari CONSENSUS CONFERENCE 2014 ISGPS

1: nomenclatura linfonodale sec. Società Giapponese del Pancreas

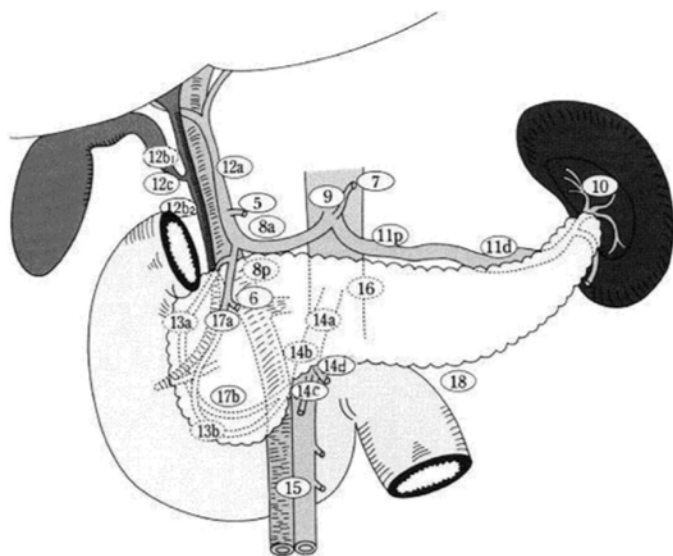


Fig 1. Japan Pancreas Society nomenclature of peri-pancreatic lymph nodes. (Adapted from Japan Pancreas Society. Classification of pancreatic carcinoma. 2nd English edition. Tokyo: Kanehara & Co. Ltd; 2003.) Lymph node stations: No. 5, Suprapyloric lymph nodes; No. 6, infrapyloric lymph nodes; No. 7, lymph nodes along the left gastric artery; No. 8a, lymph nodes in the anterosuperior group along the common hepatic artery; No. 8p, lymph nodes in the posterior group along the common hepatic artery; No. 9, lymph nodes around the celiac artery; No. 10, lymph nodes at the splenic hilum; No. 11p, lymph nodes along the proximal splenic artery; No. 11d, lymph nodes along the distal splenic artery; No. 12a, lymph nodes along the hepatic artery; No. 12p, lymph nodes along the portal vein; No. 12b, lymph nodes along the bile duct; No. 12c (located next to 12b), lymph nodes around the cystic duct; No. 13a, lymph nodes on the posterior aspect of the superior portion of the head of the pancreas; No. 13b, lymph nodes on the posterior aspect of the inferior portion of the head of the pancreas; No. 14a, lymph nodes along the proximal superior mesenteric artery; No. 14b, lymph nodes along the distal superior mesenteric artery; No. 14c, lymph nodes along the proximal superior mesenteric artery; No. 14d, lymph nodes along the distal superior mesenteric artery; No. 15, lymph nodes along the middle colic artery; No. 16, lymph nodes around the abdominal aorta; No. 17a, lymph nodes on the anterior surface of the superior portion of the head of the pancreas; No. 17b, lymph nodes on the anterior surface of the inferior portion of the head of the pancreas.

2: l' "extended lymphadenectomy" non migliora la prognosi ma peggiora la morbilità (diarrea, calo ponderale)

3: I Ln 13 e 17 (connettivo duodenopancreatico) sono sempre asportati col pezzo chirurgico

4: I Ln 14a e 14b (laterali destri SMA) vanno inclusi nella standard lymphadenectomy: frequente sede di recidiva. La linfadenectomia a 360° della SMA (extended lymphadenectomy) non migliora la prognosi e peggiora la morbilità: non va eseguita.

5: La resezione dei Ln9 (tronco celiaco) non migliora la prognosi e non è indicata.

6: Legamento epatoduodenale: fanno parte della standard lymphadenectomy i Ln 5-6-8a-12b-12c. Il livello di raccomandazione per l'asportazione di 8p non è forte.

7: I Ln 11 e 7 (a. splenica e gastrica sin) non fanno parte della "standard lymphadenectomy" e non vanno resecati.

8: Per i Ln 16 (paraortici) e 16b1 (interaortocavali) non esistono forti raccomandazioni alla resezione per la pessima prognosi correlata alla loro positività a prescindere dalla resezione stessa.

STANDARD LYMPHADENECTOMY:

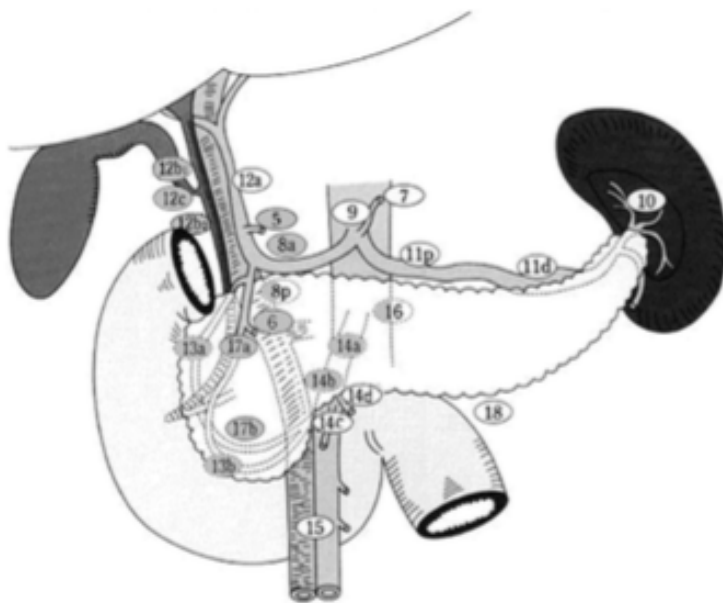


Fig 4. Standard lymphadenectomy during pancreatoduodenectomy in patients with pancreatic ductal adenocarcinoma includes: Lymph node stations—No. 5, Suprapyloric lymph nodes; No. 6, infrapyloric lymph nodes; No. 8a, lymph nodes in the anterosuperior group along the common hepatic artery; No. 12b and 12c, lymph nodes along the bile duct and around the cystic duct; No. 13a, lymph nodes on the posterior aspect of the superior portion of the head of the pancreas; No. 13b, lymph nodes on the posterior aspect of the inferior portion of the head of the pancreas; No. 14, lymph nodes along the right lateral superior mesenteric artery; No. 17a, lymph nodes on the anterior surface of the superior portion of the head of the pancreas; No. 17b, lymph nodes on the anterior surface of the inferior portion of the head of the pancreas.